

Peripartum Cardiomyopathy

MAYA GUGLIN MD, PHD
DIRECTOR, HEART FAILURE/HEART TRANSPLANTATION/MCS SERVICES
PROFESSOR, INDIANA UNIVERSITY SCHOOL OF MEDICINE
KRANNERT INSTITUTE OF CARDIOLOGY




INDIANA
CHAPTER

AMERICAN COLLEGE of CARDIOLOGY®

40 years old

- ▶ Admitted to U of KY hospital 4 years ago with shortness of breath and chronic fatigue
- ▶ Symptoms started at the end of pregnancy 3 months prior and did not resolve after delivery
- ▶ Had two prior pregnancies at 25 and 38 years of age
- ▶ First pregnancy – uneventful
- ▶ Second pregnancy – hypertension, shortness of breath, peripheral edema
- ▶ On discharge: "your heart is enlarged"
- ▶ Given a follow-up appointment but did not follow up
- ▶ The symptoms got somewhat better but never completely resolved



PMH


- ▶ Hypertension x 2 years
- ▶ TIA with slurred speech – resolved within 24 hours – 1 year ago
- ▶ Prediabetes, no treatment
- ▶ No family history of cardiac problem
- ▶ No smoking/alcohol
- ▶ Occasional cocaine use

PE

- ▶ BMI 41
- ▶ 92 bpm
- ▶ 150/85 mmHg
- ▶ No JVD
- ▶ Mild rales bilaterally
- ▶ Abdominal exam benign
- ▶ No peripheral edema

Labs

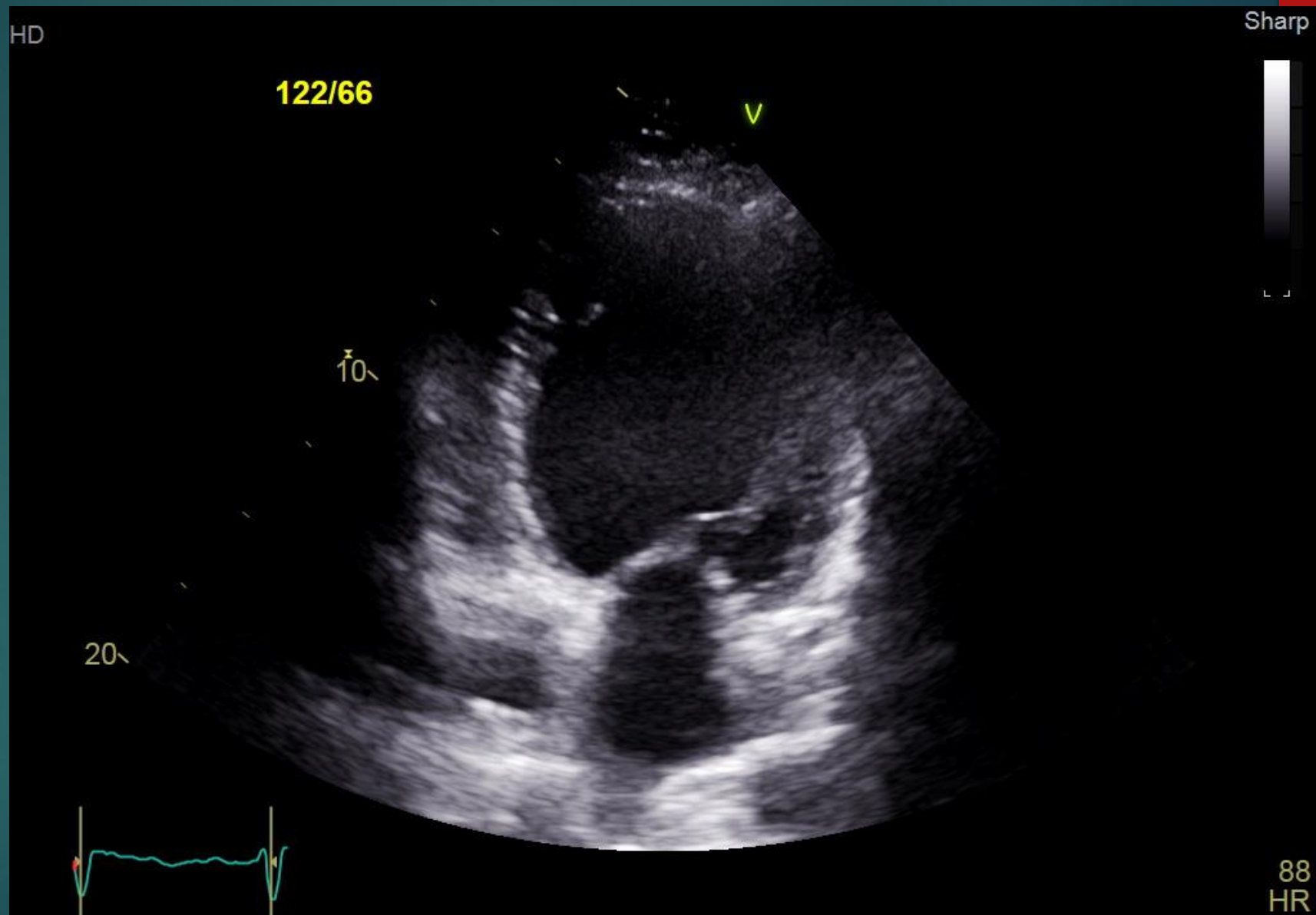
- ▶ BUN/Creatinine 40/1.6
- ▶ BNP 529 pg/mL
- ▶ HbA1C 7.1
- ▶ Troponin mildly elevated
- ▶ Toxicology screen negative

- 
- ▶ **CXR: bilateral interstitial markings consistent with mild edema**
 - ▶ **No pleural effusions**
 - ▶ **Cardiomegaly**

 - ▶ **ECG: sinus tachycardia**

 - ▶ **Echo**
 - ▶ **LVEDD 6.5 cm**

Echo





▶ **LHC: normal coronaries**

▶ **RHC**

RA 12 mmHg


PA 55/38 mmHg


Wedge 36 mmHg

Mixed SvO₂ 52%

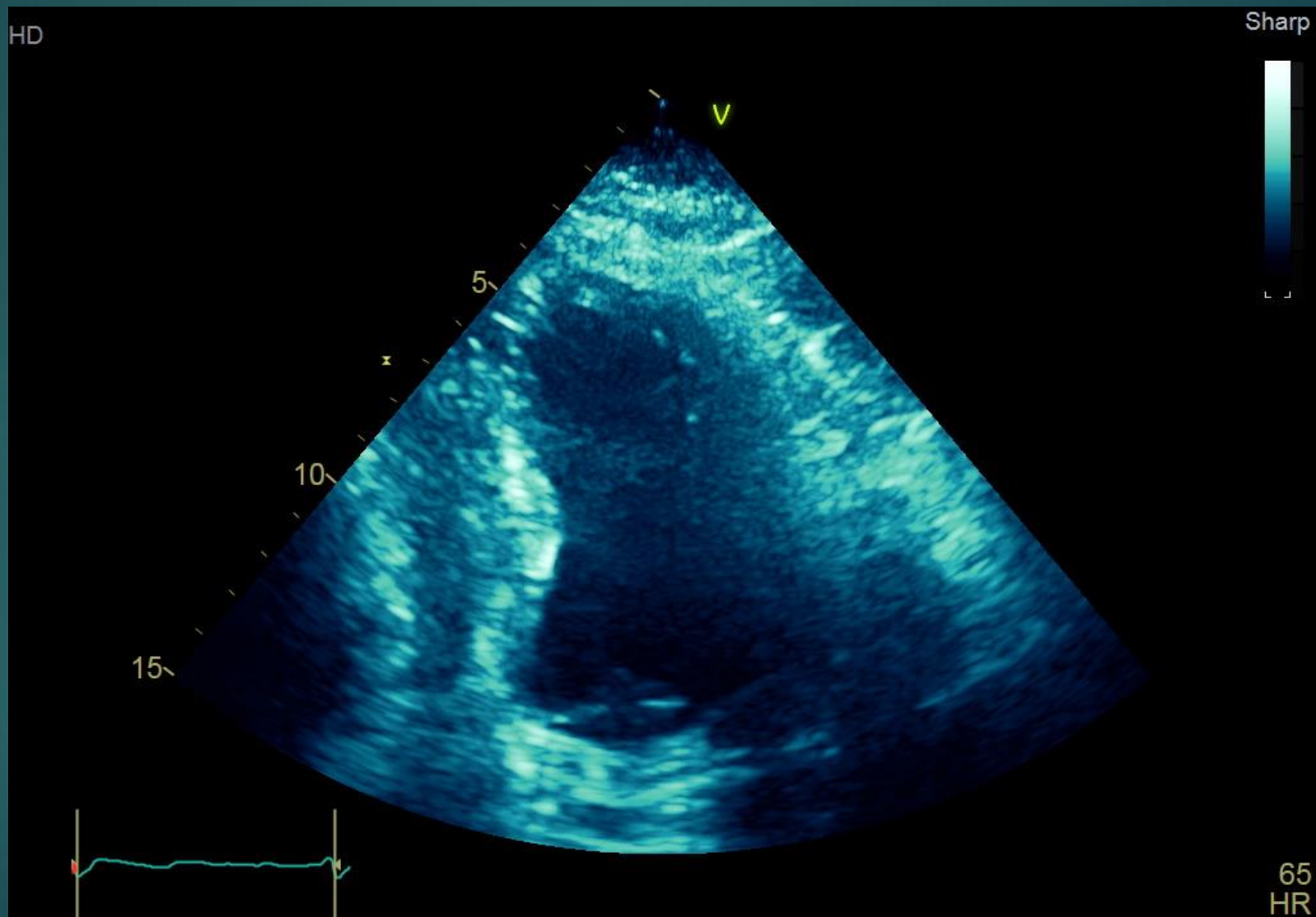
Cardiac index (Fick) 2.0 L/kg/min

▶ **Endomyocardial biopsy: non-specific findings**

- 
- ▶ **Started on torsemide**
 - ▶ **Sacubitril/valsartan**
 - ▶ **Carvedilol**
 - ▶ **Aldactone**
 - ▶ **Apixamab**


- 
- ▶ **Improvement x2 months**
 - ▶ **BP decreased**
 - ▶ **Sacubitril/valsartan discontinued**
 - ▶ **Started on IV milrinone**
 - ▶ **Did well x 5 months**
 - ▶ **Decompensated**
 - ▶ **LVAD implanted**

Echo 6 months later



Ramp in the cath lab

LVAD speed, rpms	LVAD Flow, L/min	RA, mmHg	PA, mmHg	PCWP, mmHg	CI, L/kg/min	SvO2, %
4800	4.5	14	45/20	15	2.4	62
4400	3.7	15	49/19	15	2.5	63
3800	3.2	13	45/16	14	2.6	63
3400	2.2	14	46/18	15	2.3	64
3000	1.4	13	43/17	14	2.5	63

- 
- ▶ **LVAD explanted**
 - ▶ **Felt great next 3 months on GDMT**
 - ▶ **Mildly symptomatic**
 - ▶ **9 months: milrinone dependent**
 - ▶ **11 months: re-implanted**