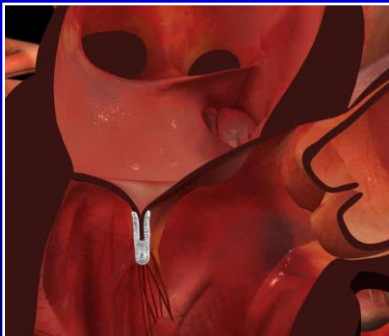



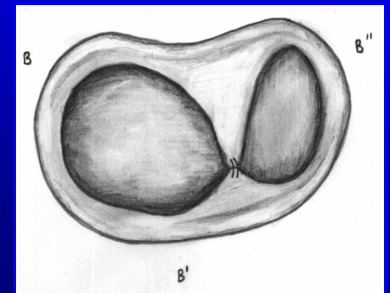
Indiana Chapter of ACC  
November 15<sup>th</sup>, 2008



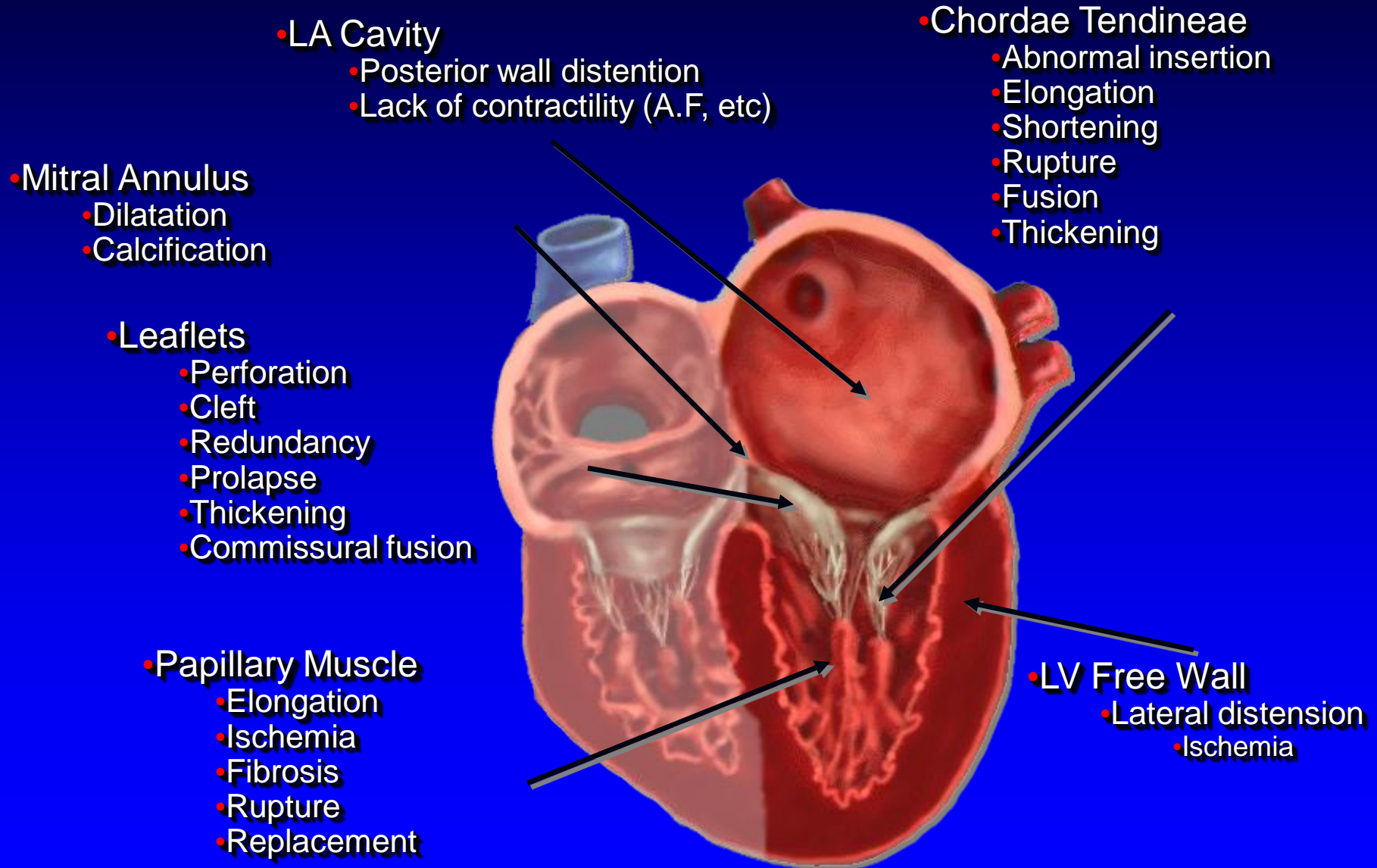
# Percutaneous Mitral Valve Repair



James B Hermiller, MD, FACC  
The Care Group, LLC  
St Vincent Hospital  
Indianapolis, IN



# Mechanisms of Mitral Regurgitation



# Percutaneous mitral valve repair

---

- Edge to edge repair
- Annular intervention
  - Coronary sinus
  - Direct annular repair
- Percutaneous replacement

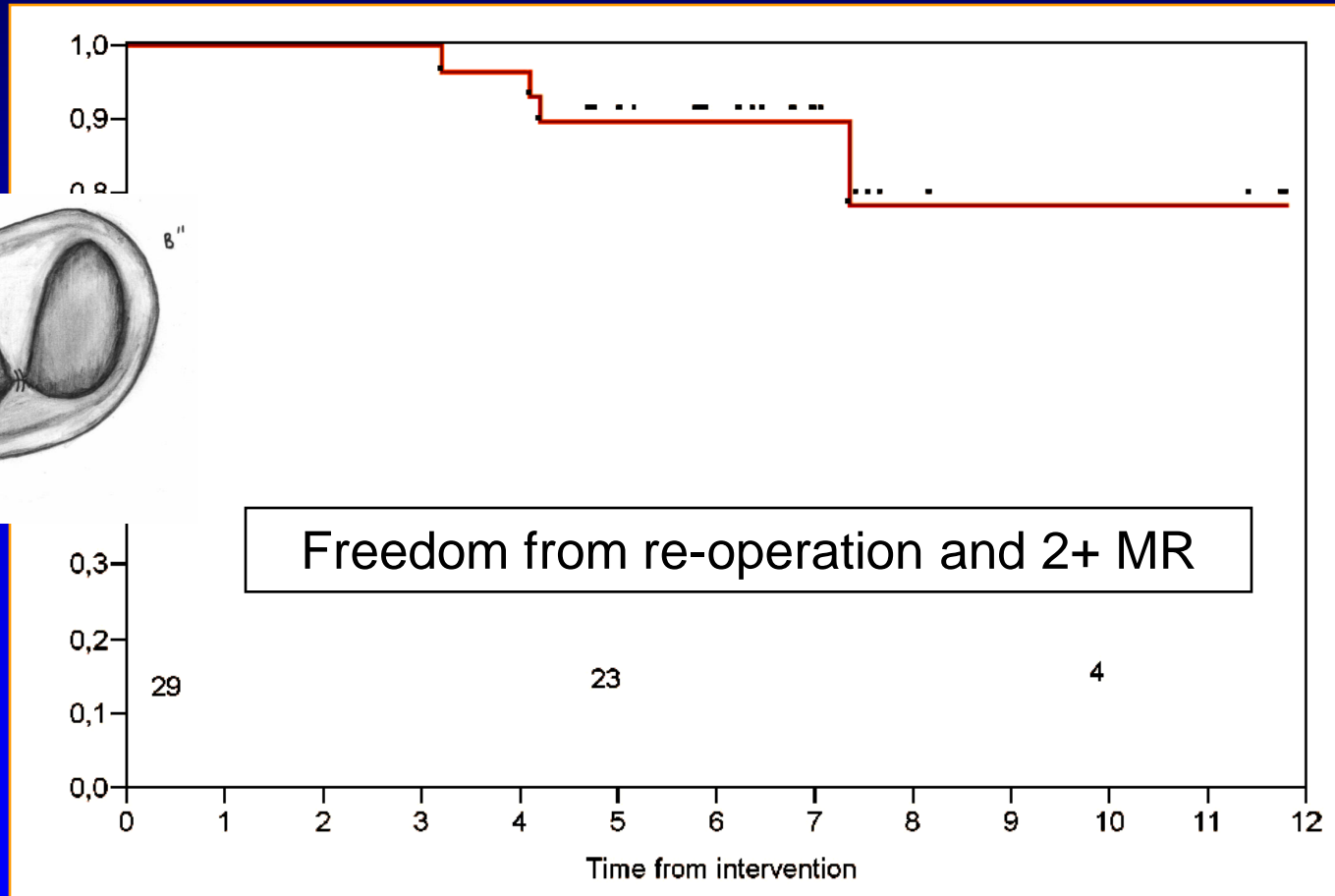
## **Surgical isolated edge-to-edge mitral valve repair without annuloplasty: clinical proof of the principle for an endovascular approach**

Francesco Maisano\*, MD; Giorgio Viganò, MD; Andrea Blasio, MD; Antonio Colombo, MD; Chiara Calabrese, Ottavio Alfieri, MD

*San Raffaele University Hospital, Milano, Italy*

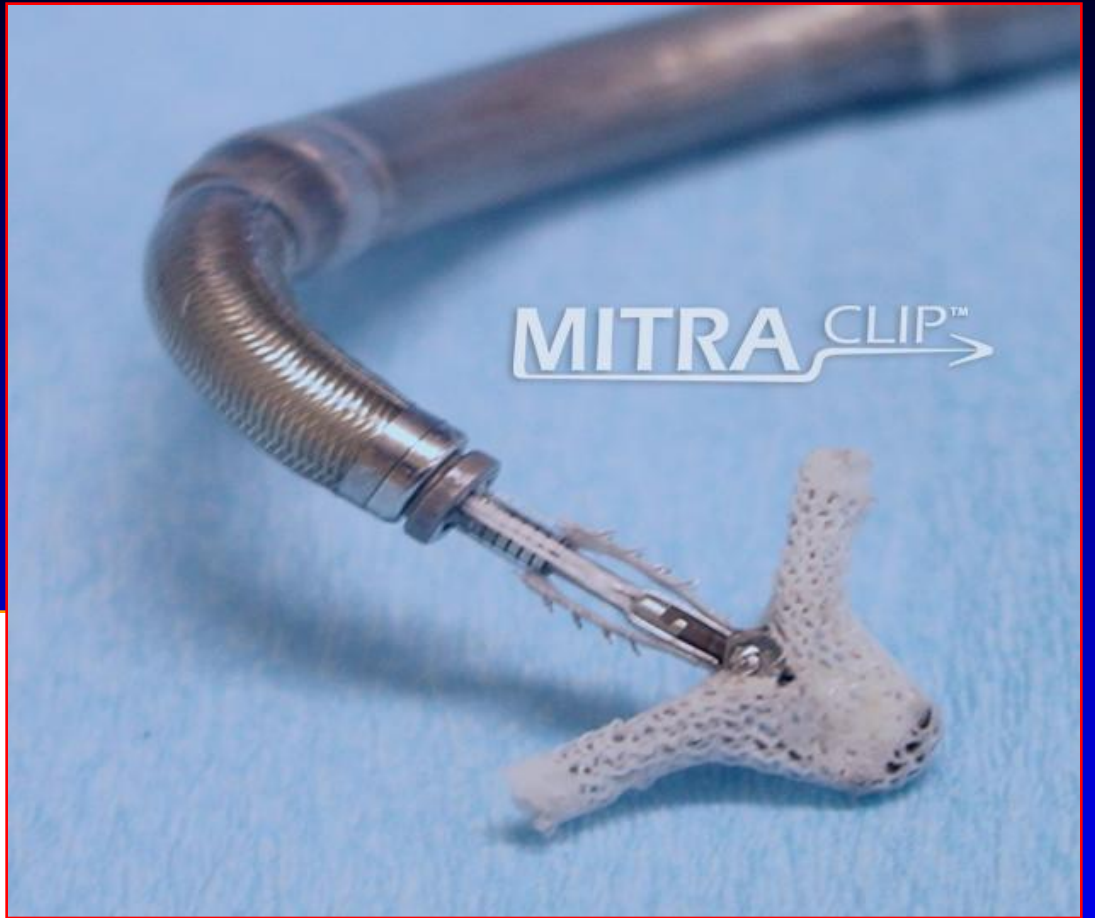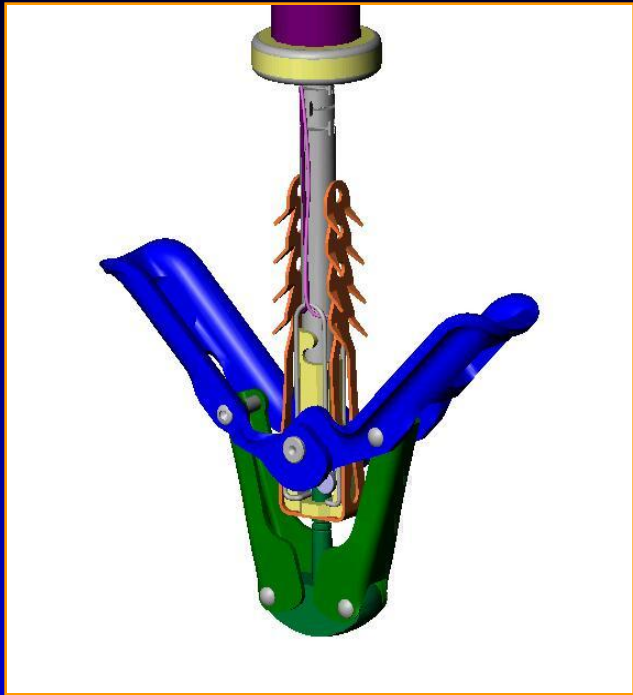
# Surgical isolated edge-to-edge mitral repair without annuloplasty

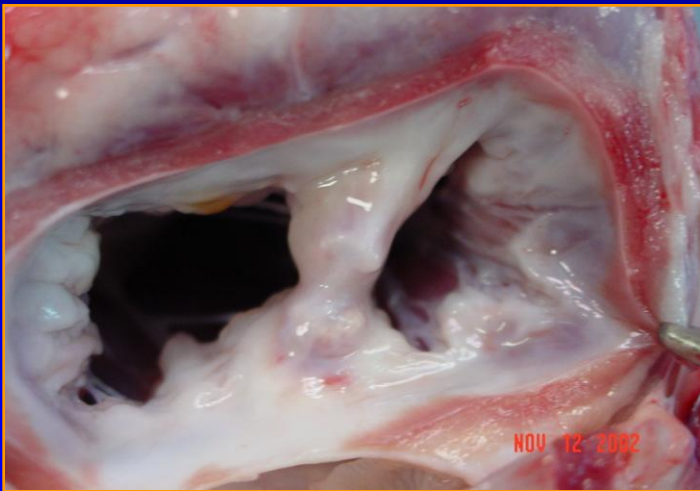
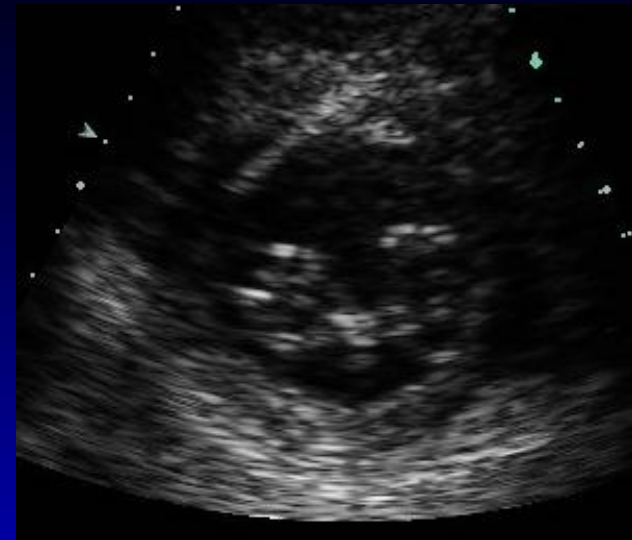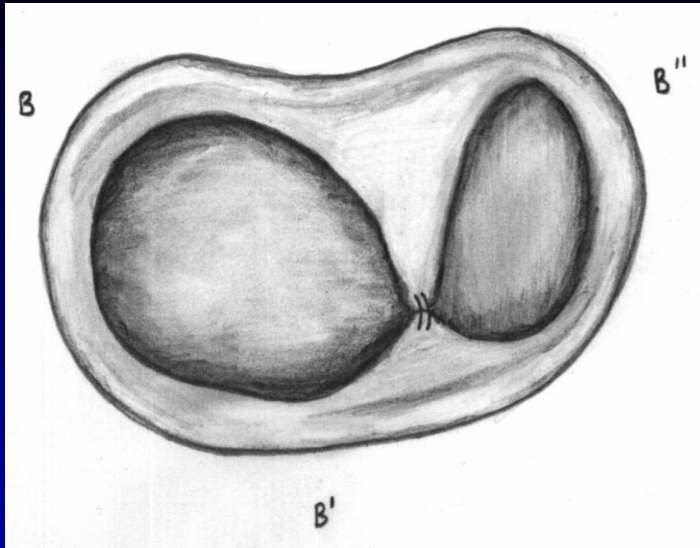
*clinical proof of principle for an endovascular approach*



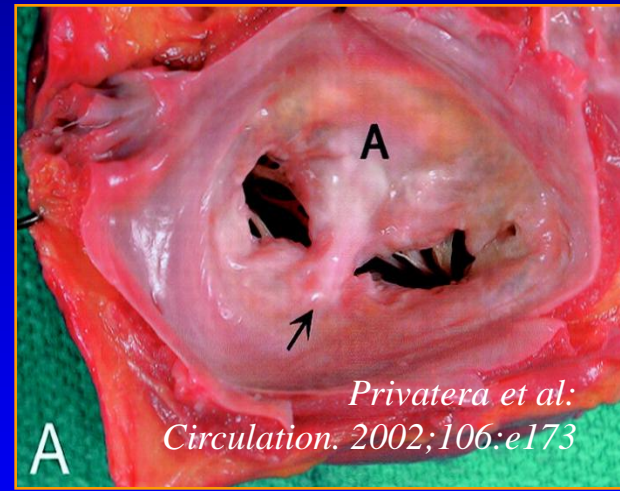
Maisano F, Vigano G, Blasio A, Columbo A, Calabrese C, Alfieri O

*Eurointervention* 2:181-186, 2006





Clip repair in porcine heart  
(6 months post repair)



Suture repair in human heart  
(4 years post repair)

*Fann JJ, St Goar FG, Komtebedde J, Oz MC, Block PC, Foster E, Butany J, Feldman T, Burdon TA: Beating heart catheter-based-edge-to-edge mitral valve procedure in a porcine model; efficacy and healing response. Circulation 110:988-993, 2004*

# Edge to Edge & MitraClip Concepts

---

## ■ Facilitates proper leaflet coaptation

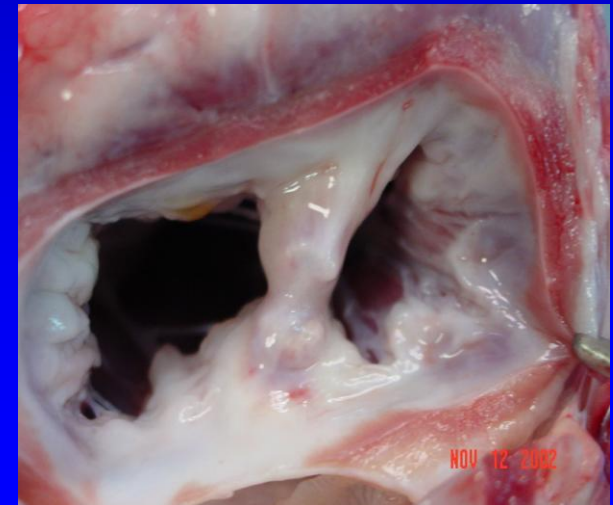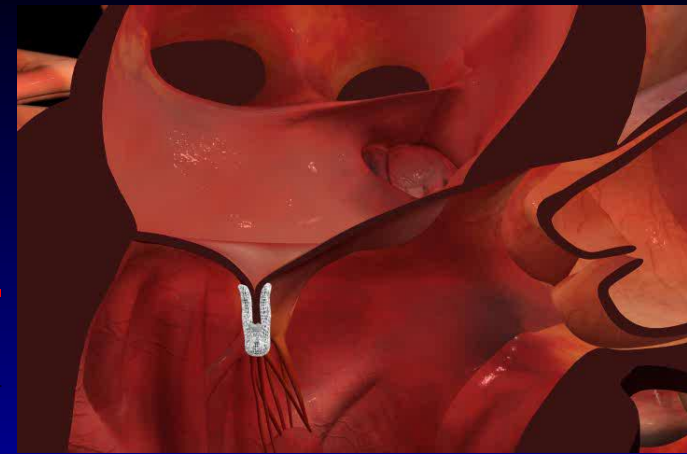- Mechanical solution to a mechanical problem
- Degenerative - Anchor flail and prolapsed leaflets (similar to chordal transfer/replacement)
- Functional - Coapt tethered leaflets to reduce time and force required to close valve
- Reduces LV volume overload by reducing MR

## ■ Creates tissue bridge

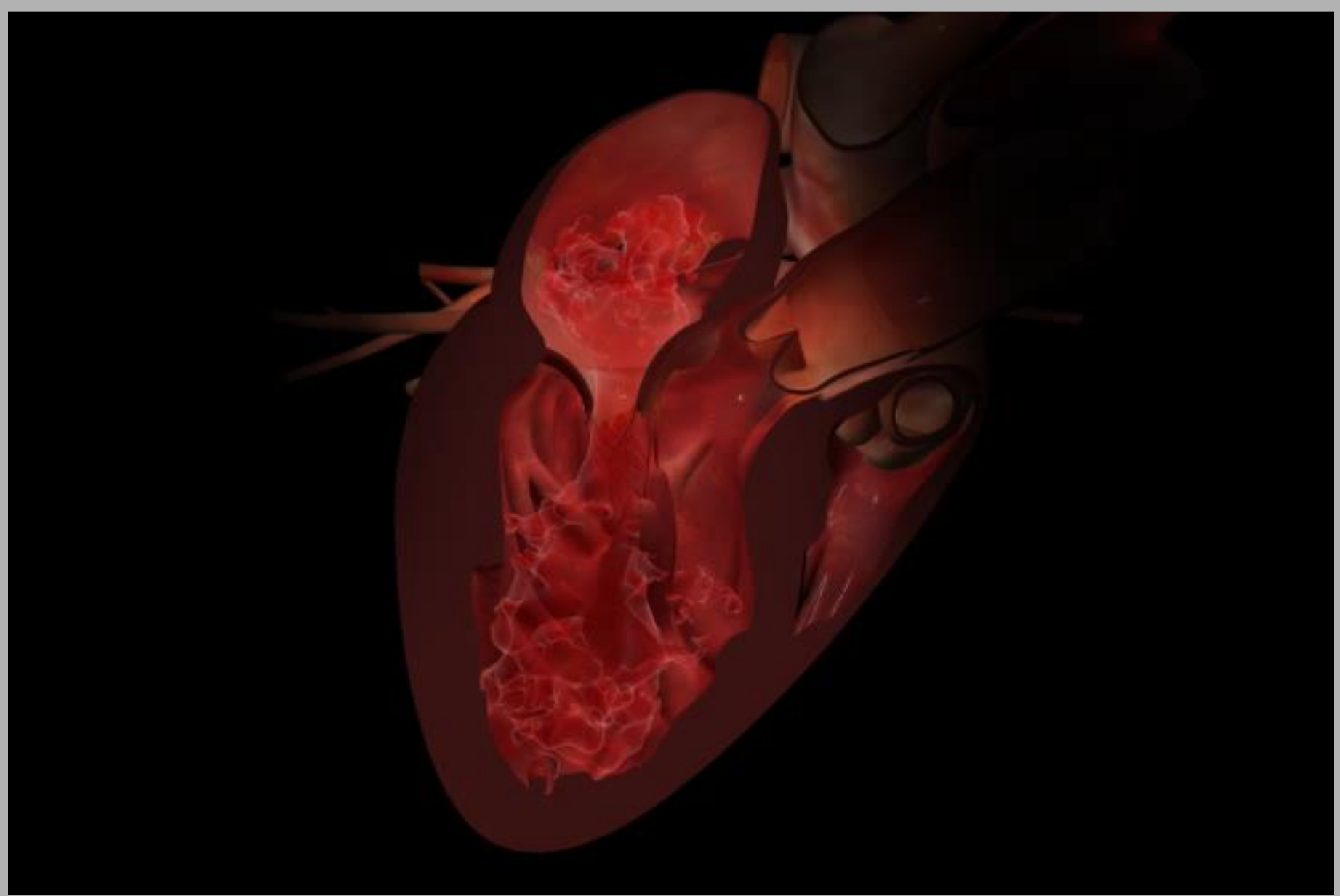
- Limits dilatation of annulus
  - Septal-lateral (A-P) dimension
- Supports durability of repair

## ■ Restrains LV wall

- Limits LV dilatation



Porcine model, 6M



# EVEREST Trial: Key Eligibility Criteria

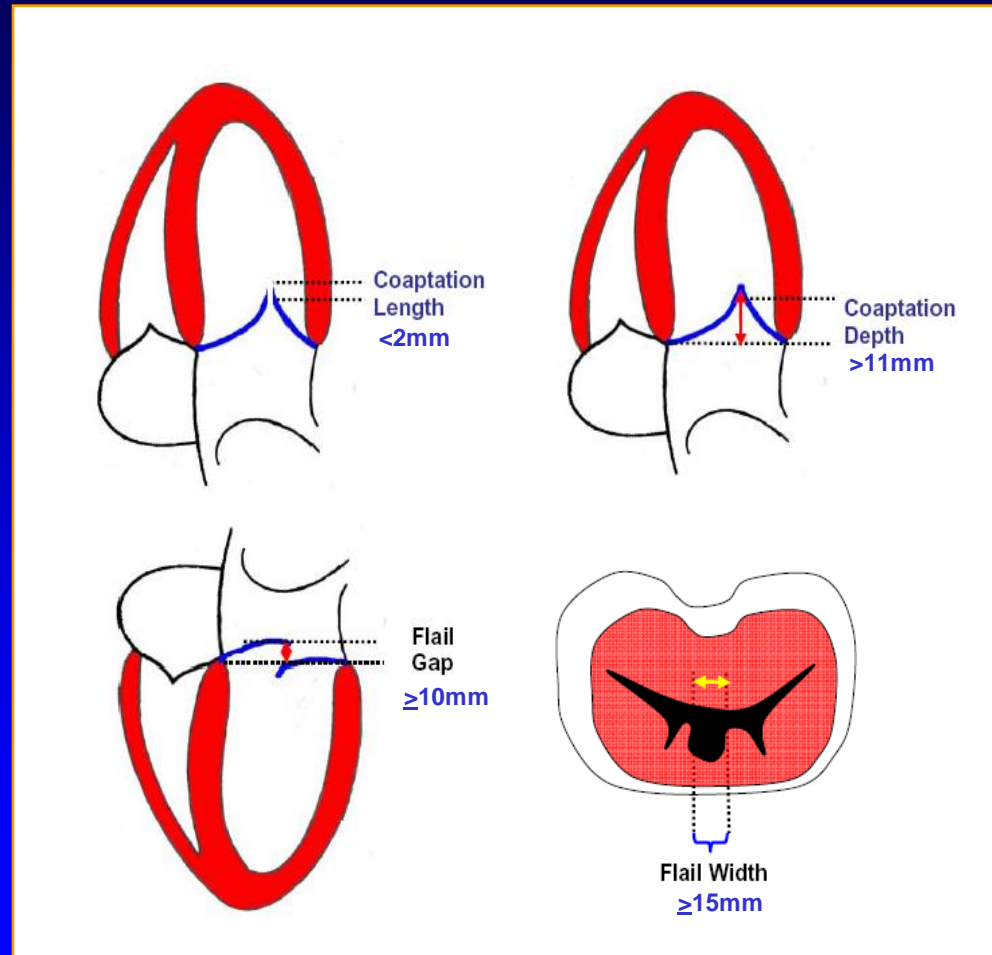
---

- Age 18 years or older
- Moderate to severe (3+) or severe (4+) MR
  - *Symptomatic*
  - *Asymptomatic with LVEF < 60% or LVESD > 40mm*  
ACC/AHA Guidelines, Circ. 114;450,2006
- MR originates from A2-P2 mal-coaptation
- Candidate for mitral valve surgery including CPB
- Transseptal deemed feasible
- Key Exclusions
  - *EF < 25% or LVESD > 55 mm*
  - *Renal insufficiency*
  - *Endocarditis, rheumatic heart disease*

# Anatomic Eligibility

## Leaflet mal-coaptation resulting in MR

- Sufficient leaflet tissue for mechanical coaptation
- Non-rheumatic/endocarditic valve morphology
- Protocol anatomic exclusions
  - Flail gap  $>10\text{mm}$
  - Flail width  $>15\text{mm}$
  - LVIDs  $>55\text{mm}$
  - Coaptation depth  $>11\text{mm}$
  - Coaptation length  $<2\text{mm}$



# EVEREST I & II Enrollment

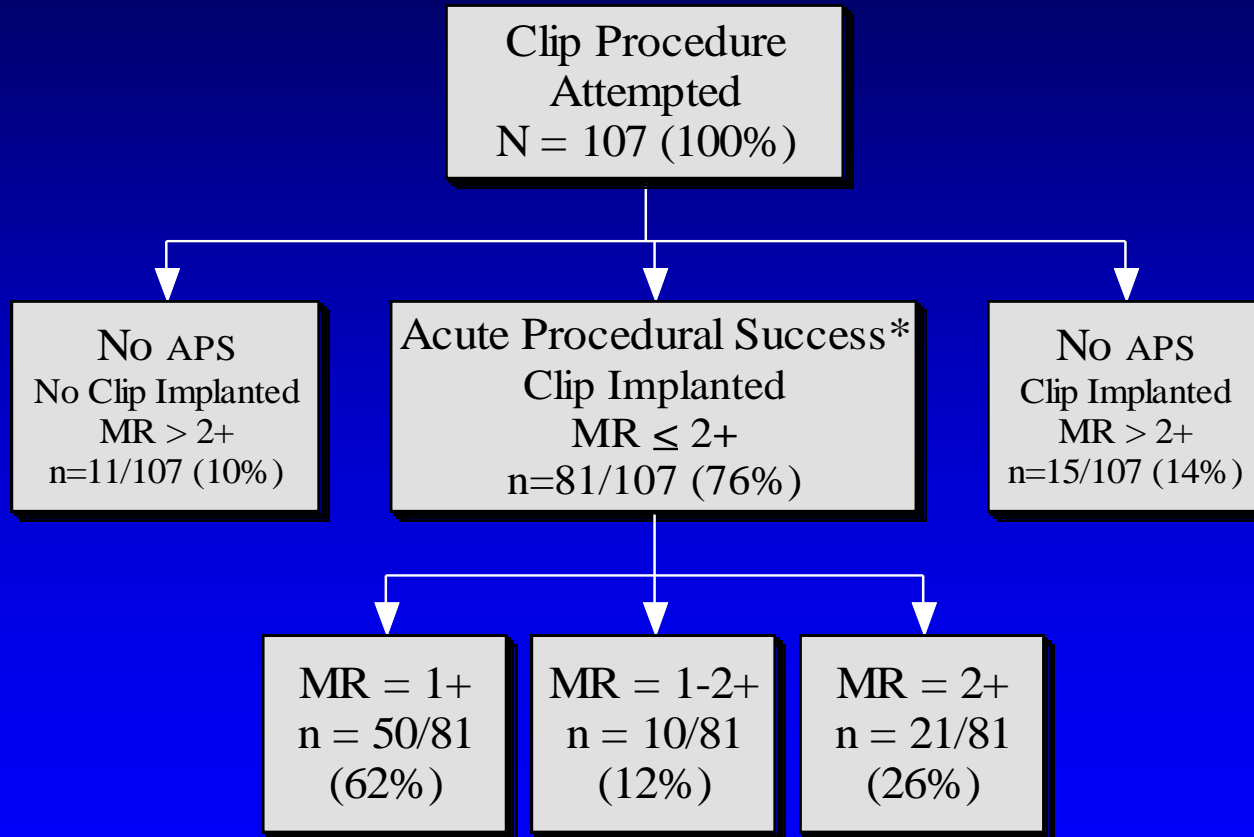
(9/17/08)

<b>Enrollment</b>	<b>Population</b>	<b>n</b>
EVEREST I Feasibility (completed)	Registry patients	55
EVEREST II	Roll-in	60
Randomized n=279 (100% enrolled)	Randomized Clip	184
	Randomized Surgery	95
EVEREST II	High Risk Registry	78
<b>Total enrolled</b>		<b>472</b>

# EVEREST Preliminary Cohort

## Efficacy Results through Discharge

N = 107

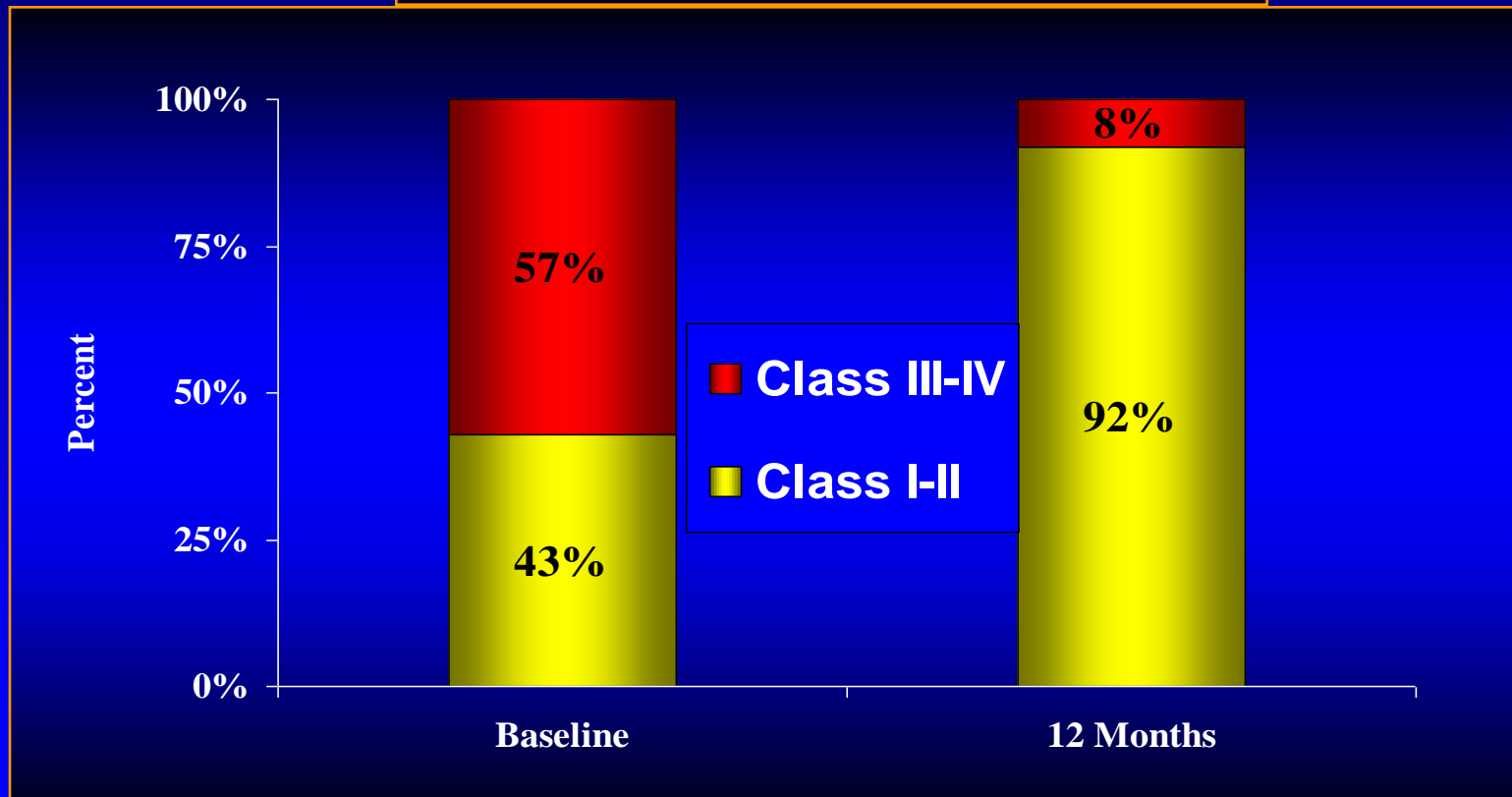


\* **Acute Procedural Success (APS):** Defined as placement of one or more Clips resulting in discharge MR severity of 2+ or less, as determined by Core Lab.

# EVEREST Preliminary Cohort Clinical Improvement after APS

12-Months vs. Baseline (Matched Data\*, n = 53)

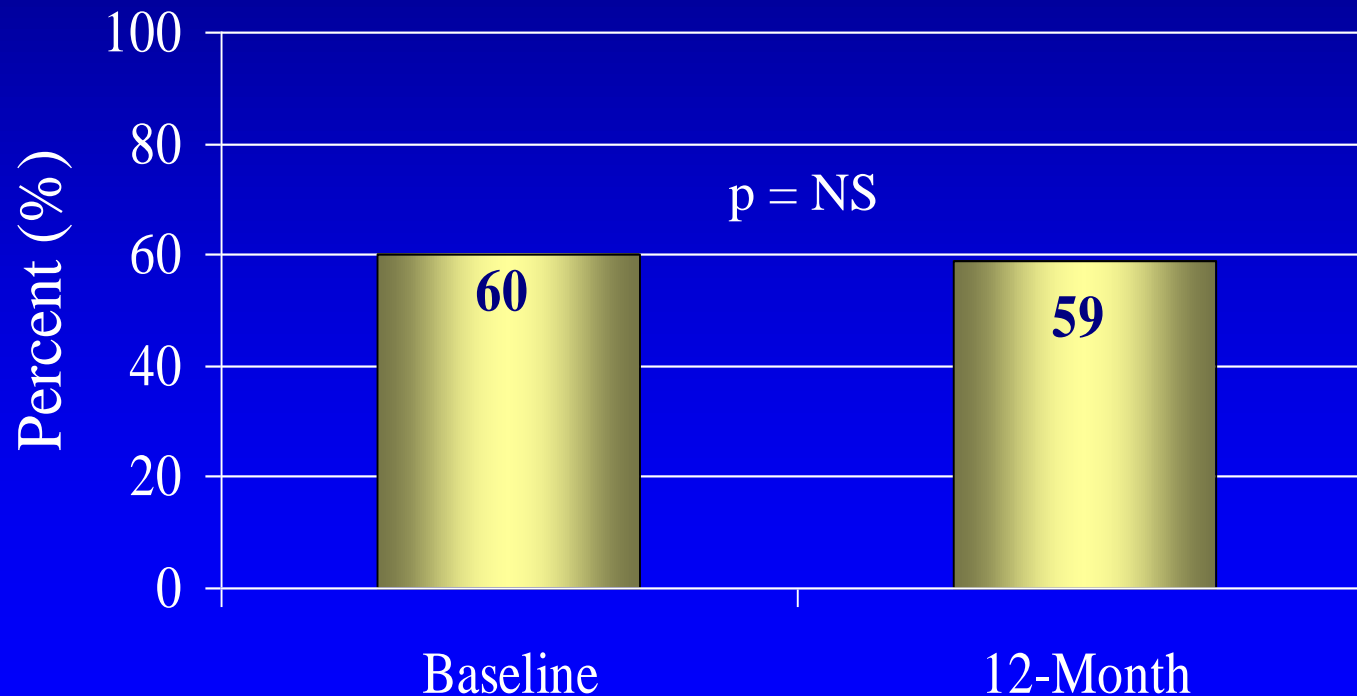
**77% (41/53) Improved**  
**17% (9/53) No Change**  
**6% (3/53) Worsened w/o MR > 1+**



\* All APS patients excluding those that went to MV surgery post-Clip prior to 12-months or have not reached 12-month follow-up

# EVEREST Preliminary Cohort Ejection Fraction APS Patients\* (matched data, n = 54)

## Ejection Fraction



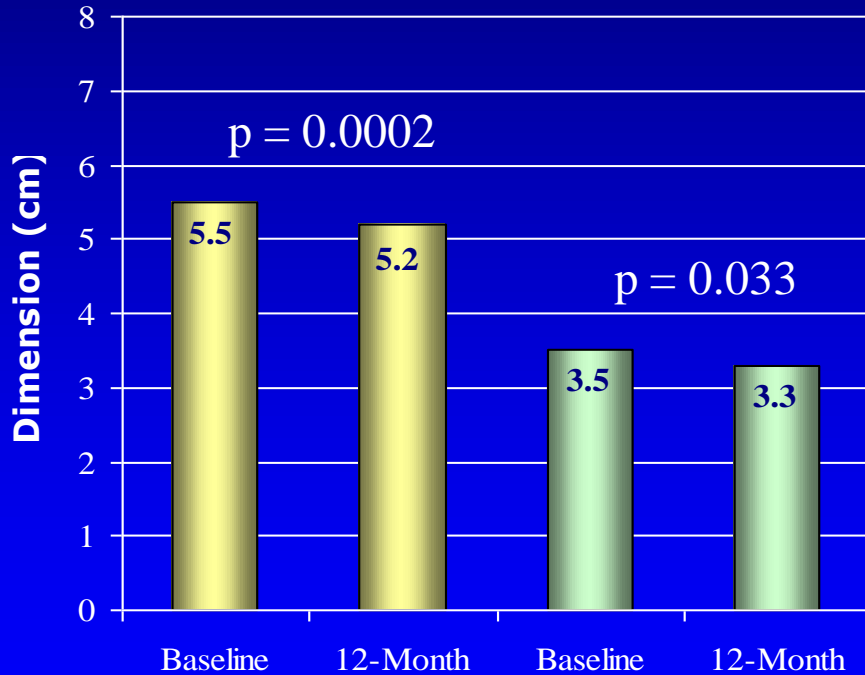
\* Excludes patients that went to MV surgery post-Clip prior to 12-months or have not reached 12-months

# EVEREST Preliminary Cohort

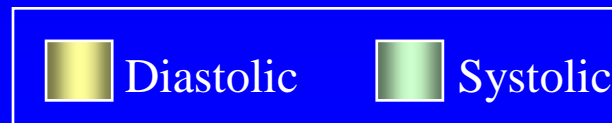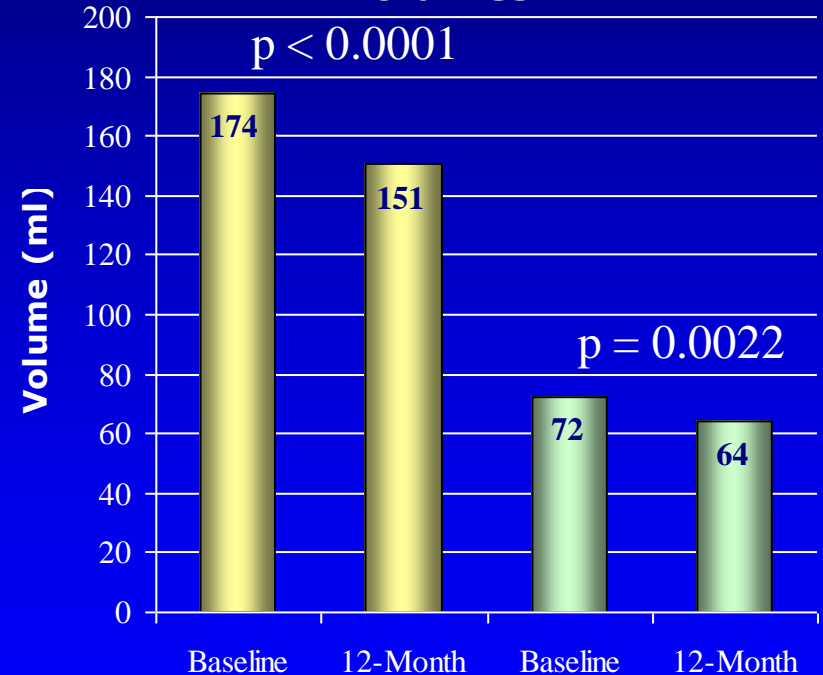
## Reverse LV Remodeling

### Matched Data, APS Patients (matched data\*, n = 54)

#### LV End Diastolic & Systolic Dimensions



#### LV End Diastolic & Systolic Volumes

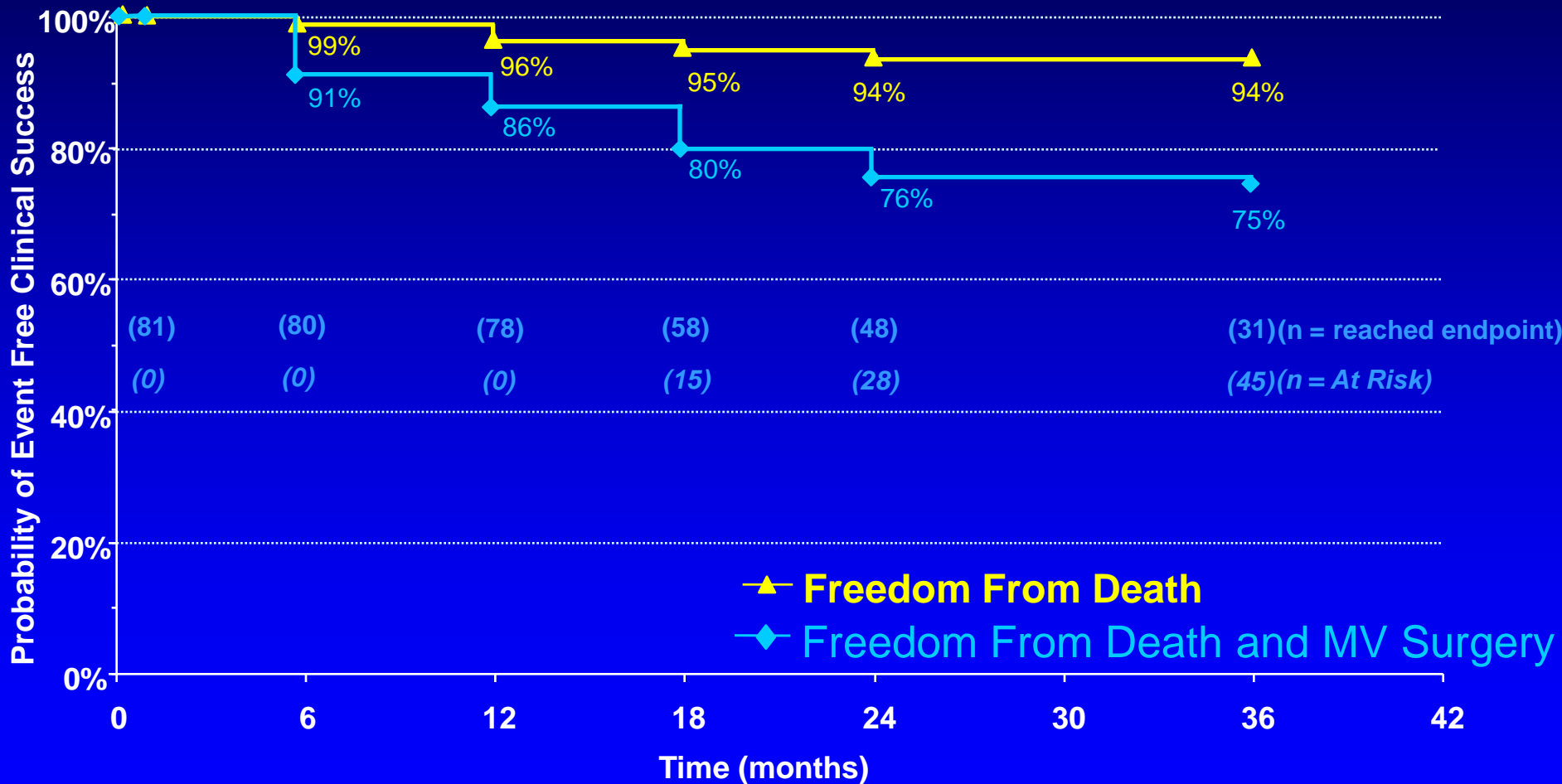


\* All APS patients excluding those that went to MV surgery post-Clip prior to 12-months or have not reached 12-month follow-up

# EVEREST Preliminary Cohort

## Freedom from Death and MV Surgery

### Kaplan-Meier, APS Patients N = 81

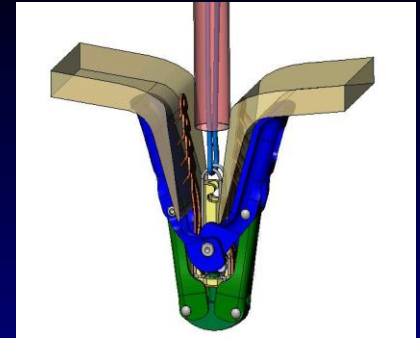
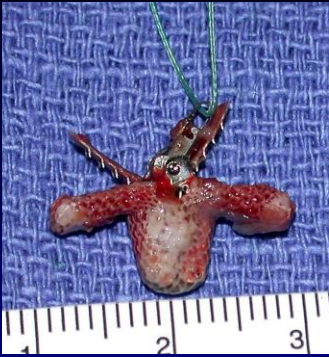

# EVEREST Preliminary Cohort

## Data Summary

- Significant MR reduction in DMR and FMR patients
  - $\leq 1+$  MR in majority of successful cases
  - Durable up to at least 36 months
- NYHA Class Improved
- Significant reverse LV remodeling demonstrated
- Decreasing procedure time - controlled procedure
- Low complication rate and short hospital stay
- 89% (95/107) of all EVEREST Preliminary Cohort patients underwent either percutaneous or surgical repair
- Surgical options preserved - repair in 67%

# *“Nothing to Lose” Standard*


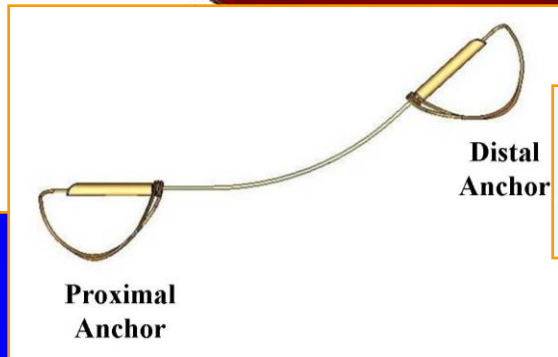

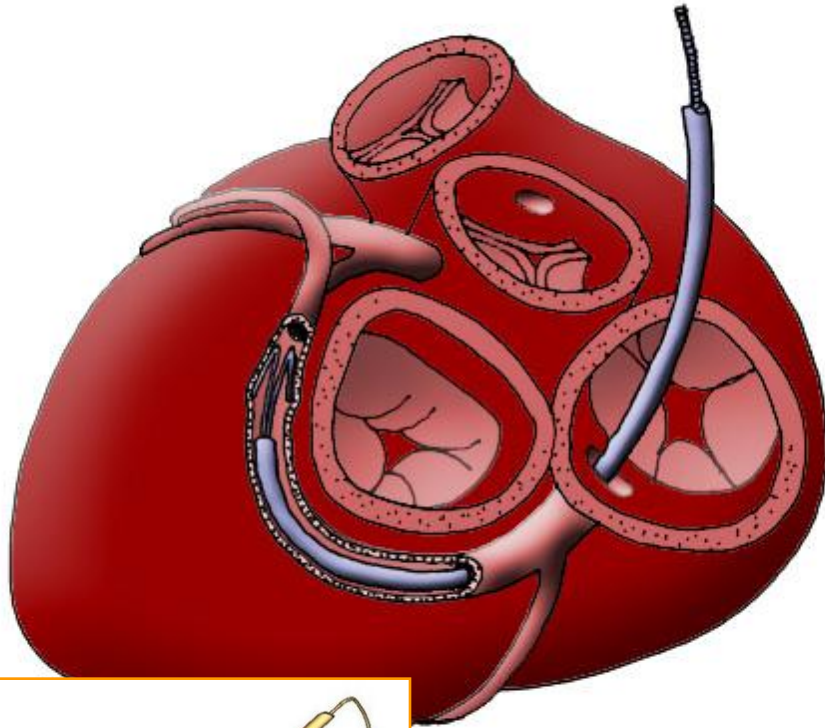


## Failed MitraClip procedures:


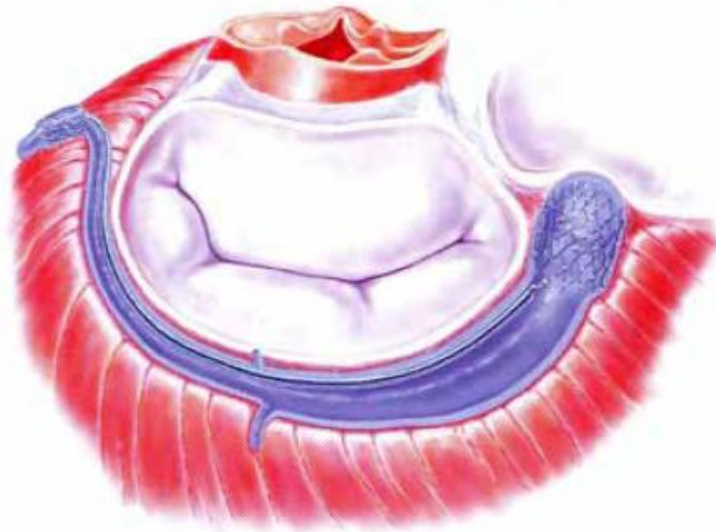
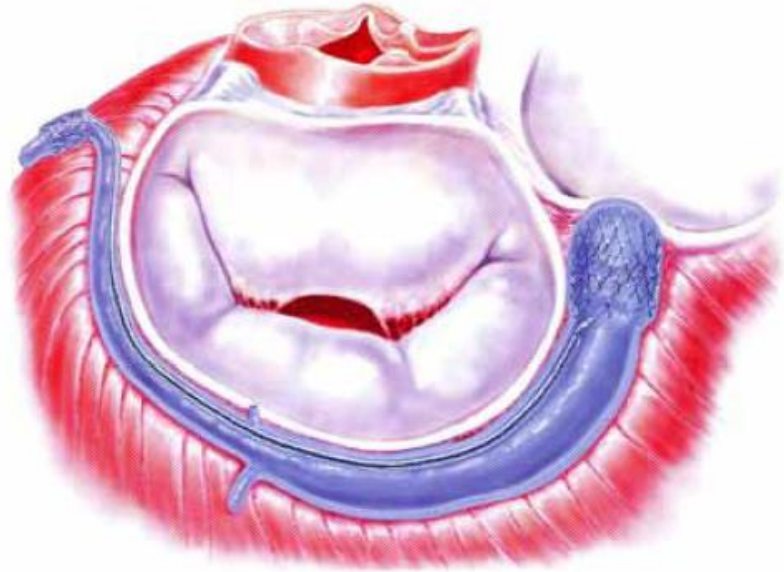
- no mortality
- no significant morbidity
- no detrimental effect on subsequent surgical management up to 18 mos

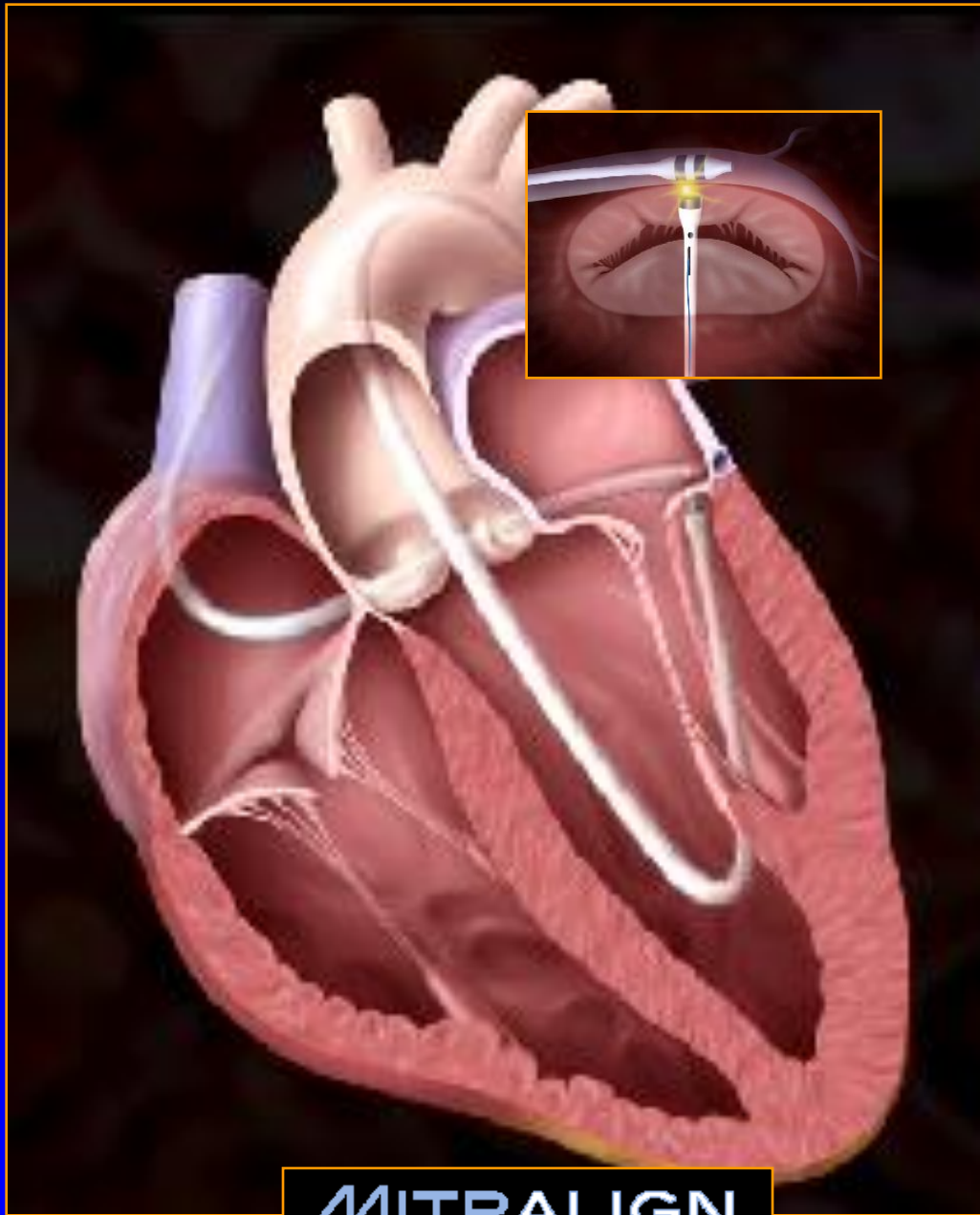
*Dang NC. Aboodi MS. Sakaguchi T. Wasserman HS. Argenziano M. Cosgrove DM. Rosengart TK. Feldman T. Block PC. Oz MC. Surgical revision after percutaneous mitral valve repair with a clip: initial multicenter experience. Annals of Thoracic Surgery. 80(6):2338-42, 2005*

# CARILLON Mitral Contour System: Coronary Sinus

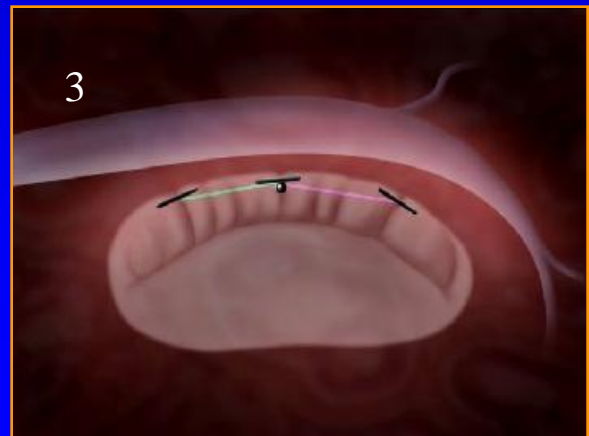
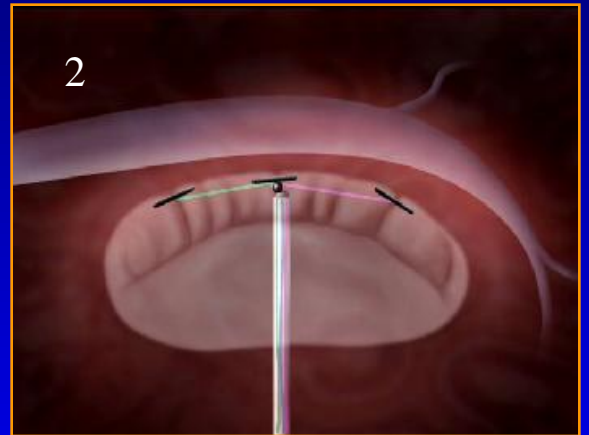
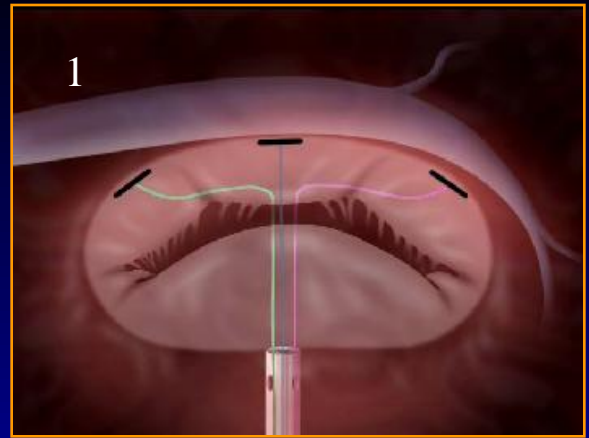


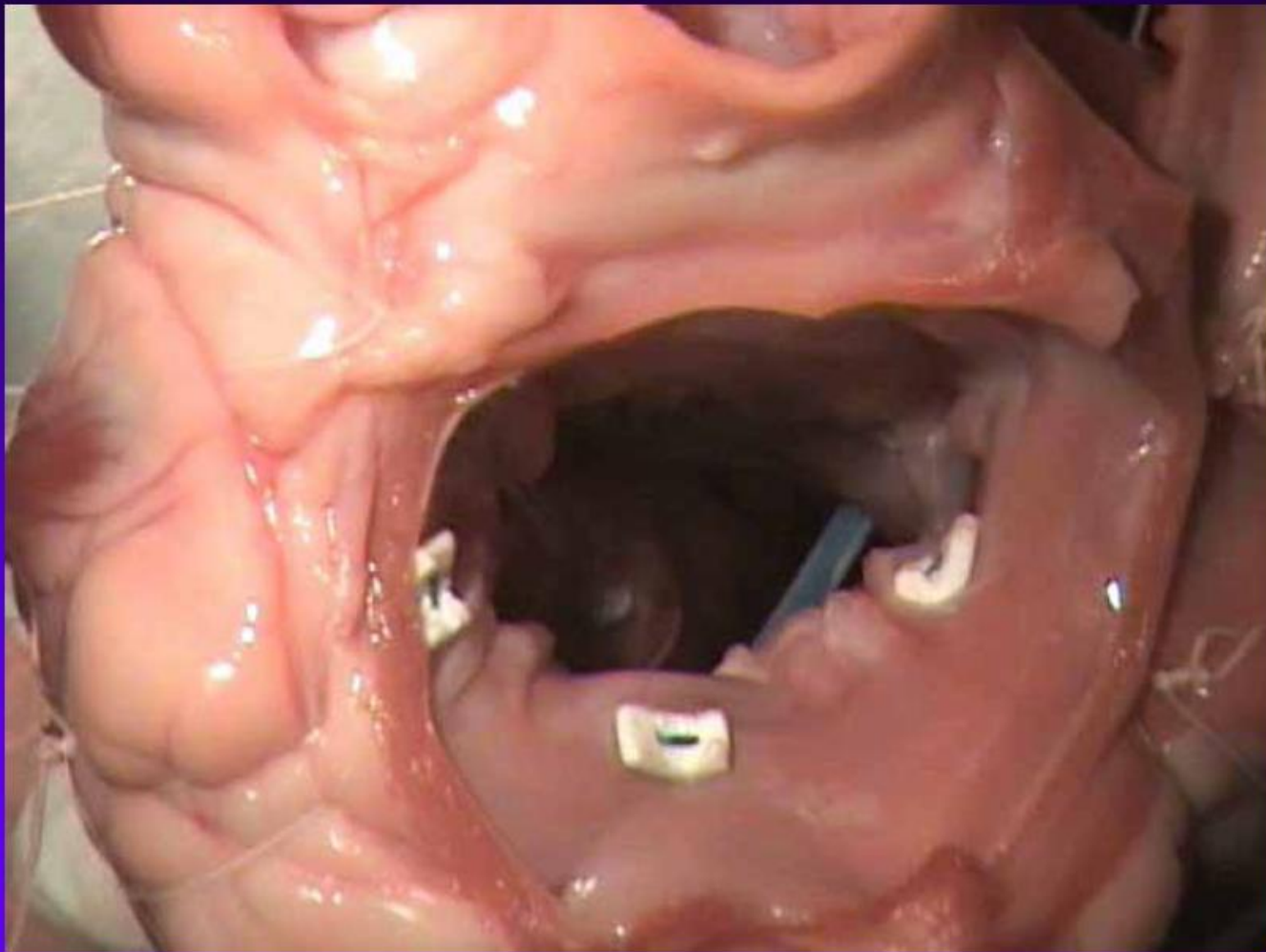
# The MONARC system Delayed Release-*in situ*



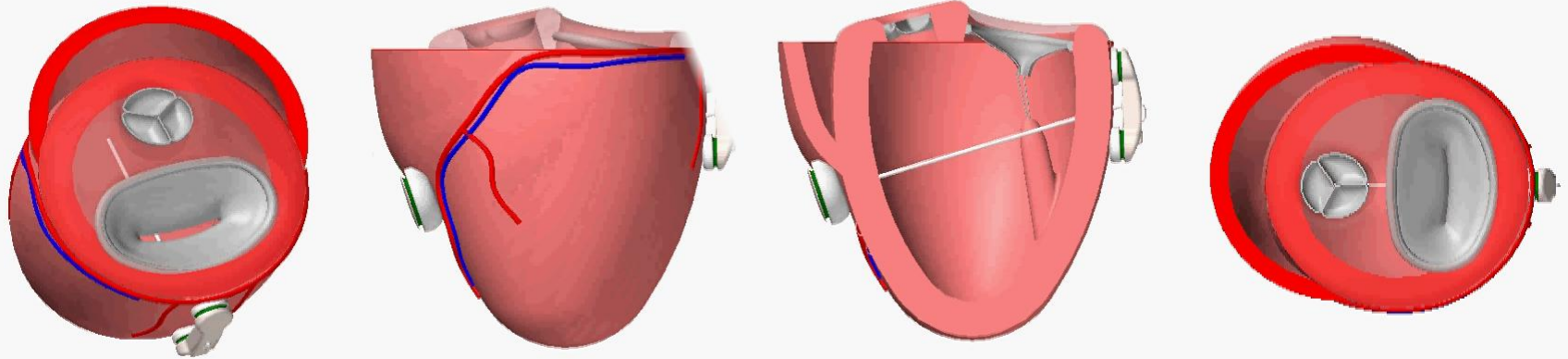


**MITRALIGN**  
Incorporated





# The Myocor Surgical Coapsys System



# Endovalve Inc.

## Percutaneous Mitral Valve Replacement

---

- Rationale:
  - Surgical repair is the gold standard (esp. degen.)
  - MV replacement still performed in ~50% of pts
  - Results with full valve sparing technique and latest generation bioprostheses rival repair results
  - Percutaneous repair unlikely to reduce MR as well as surgery
- Endovalve's Perc MV Replacement:
  - Positive (active) anchoring
  - Rigidity and structure not stent based
  - Single piece deployable and re-deployable
  - Bi-stable structure with good folding characteristics
- Potential Clinical Advantages:
  - Reduces MR as well as surgery
  - Takes advantage of improving durability of bioprosthetic leaflets
  - Full valve-sparing (as good as repair)

